

## HISTOPATHOLOGICAL EVALUATION OF *Glycyrrhiza glabra* ON ASPIRIN INDUCED GASTRIC ULCER IN MICE

Tanzeela Awan<sup>1</sup>, Bilal Aslam<sup>1,\*</sup>, Ijaz Javed<sup>1</sup>, Tanweer Khaliq<sup>1</sup>, Asghar Ali<sup>1</sup> and Zia-ud-Din Sindhu<sup>2</sup>

<sup>1</sup>Institute of Pharmacy, Physiology and Pharmacology, University of Agriculture, Faisalabad-38040, Pakistan; <sup>2</sup>Department of Parasitology, University of Agriculture, Faisalabad-38040, Pakistan.  
\*Corresponding author's e-mail: bilal.aslam@uaf.edu.pk

Non-steroidal anti-inflammatory drugs (NSAIDs) have been frequently used for their anti-inflammatory, antipyretic and analgesic effects. Despite of such actions, these drugs also cause gastrotintestinal injury and produce gastric ulcers. In current study, antiulcer activity of *Glycyrrhiza glabra* was evaluated in adult male albino mice. Gastric ulcer was induced by administering the high dose of aspirin to male adult albino mice. Treatment protocol was made for seven days. Group 1 was fed on normal diet, group 2 was given aspirin and group 3 was provided with standard treatment for ulcer, omeprazole along with aspirin. While groups 4, 5 and 6 were administered *G. glabra* roots powder at 250, 500 and 750 mg/kg body weight respectively, together with aspirin. Histopathological analysis was carried out to determine the gastroprotective activity of *G. glabra*. The results suggest that *G. glabra* has potent gastroprotective effect at highest dose.

**Keywords:** NSAIDs, *Glycyrrhiza glabra*, aspirin, omeprazole, gastroprotective, histopathology

### INTRODUCTION

Ulcer is the wound that perforate the muscularis mucosa of stomach or duodenum either it is acute or chronic and is formed when there is imbalance between mucosal offensive factors that include scathing ability of gastric hydrochloric acid and digestive power of pepsin and also the bile versus defensive factors that include the ability of gastric and duodenal mucosa containing mucus to defy these corrosive powers (Goel and Bathacharya, 1991). As far as the causes of ulcer are concerned, these may include the infection caused by a bacteria named as *Helicobacter pylori* and the use of non-steroidal anti-inflammatory drugs (NSAIDs) including aspirin, diclophenac, paracetamol, indomethacin and another class of drug may also cause ulcers i.e. clopidogral and stress are most important and most common reasons for gastric ulcer (Padussis and Pappas, 2010). *H. pylori* are well known as a major reason of gastrointestinal problems (Kusters *et al.*, 2006; Malfertheiner *et al.*, 2007).

The management of gastric or peptic ulcers can be done by reducing the amount of stomach acid produced and by raising the defense of stomach wall (Hoogerwerf and Pasricha, 2001). Proton pump inhibitors and Histamine receptor blocking drugs are the two most important categories of synthetic agents of choice for the treatment of gastric ulcer. Triple therapy (having combination of two antibiotics and a proton pump inhibitor) is most frequently used for the management of peptic ulcer (Asaka *et al.*, 2003; Holtmann and Howden, 2004; Gisbert and Pajares, 2005).

*Glycyrrhiza glabra* (*G. glabra*) which is also named as licorice in English is one of the most extensively used and

oldest herbal agent. This herb belongs to family *Fabaceae*. Licorice roots consist of wrinkled, fibrous wood, which grow in horizontal direction under the ground and are long and cylindrical in shape. The extract of licorice is sweetened in taste and can be used instead of sugar. Its sweet taste is due to its main component that is glycyrrhizin which is 50 times sweeter than table sugar (Hanrahan, 2001). *G. glabra* have most important bioactive constituents like triterpenes, flavonoids and polysaccharides (Seki *et al.*, 2011). It possesses antimicrobial (Ahn *et al.*, 2012; Long *et al.*, 2013), antiviral (Huang *et al.*, 2012), anti-inflammatory (Chandrasekaran *et al.*, 2011) and antitumor (Li *et al.*, 2014; Wang *et al.*, 2013). It has also numerous uses in traditional drugs to cure inflammatory and allergic diseases (Shin *et al.*, 2007). Keeping in view its medicinal value gastroprotective activity of *G. glabra* was evaluated in current study.

### MATERIALS AND METHODS

**Experimental animals:** Thirty six adult albino mice of either sex, weighing between 175±20.5 g were purchased from the local market of Faisalabad and housed at experimental animal room, Department of Physiology and Pharmacology, University of Agriculture, Faisalabad, Pakistan. The mice were kept in separate iron cages. They were kept inside a room under controlled temperature ranging from 22±2°C and relative humidity (65-70%). A twelve hour light dark cycle was provided artificially to the animals. After acclimatization the animals were divided into six groups, including six animals in each group. Further, the institutional

ethical committee of University of Agriculture Faisalabad approved all procedures adopted in this study.

**Plant material:** *G. glabra* roots were purchased from the local market of Faisalabad. The plant material was authenticated by Department of Botany, University of Agriculture Faisalabad. The samples were preserved in the Pharmacology laboratory of Department of Physiology and Pharmacology, University of Agriculture Faisalabad. The material to be used was further dried under the shade and was later finely powdered with the help of a special electrical grinder (50 cycles, 1450 R.P.M, Sohrab electrical industries, Pakistan). Five ml distilled water was used to dilute the *G. glabra* root powder before administration to the mice.

**Feed and drugs:** The mice were provided normal routine feed till the completion of experiment twice a day and water was available for 24 h. Aspirin 200 mg/kg was used to induce gastric ulcer in all groups except normal control for a period of 7 days (Brzozowski *et al.*, 2000). Omeprazole was used as synthetic anti-ulcer drug in study and was administered orally at a dose rate of 20 mg/kg (Herbert *et al.*, 2011).

**Treatment protocol:** All mice divided into groups and given different treatments via stomach tube as presented in Table 1.

**Surgical procedures:** The animals were fasted for at least 24 h before the surgical procedure. On the 7<sup>th</sup> day of experiment these animals were sacrificed. The mice were sacrificed one by one and then the stomach of the animal was isolated with the help of sharp scissors. The stomach was cut along the greater curvature.

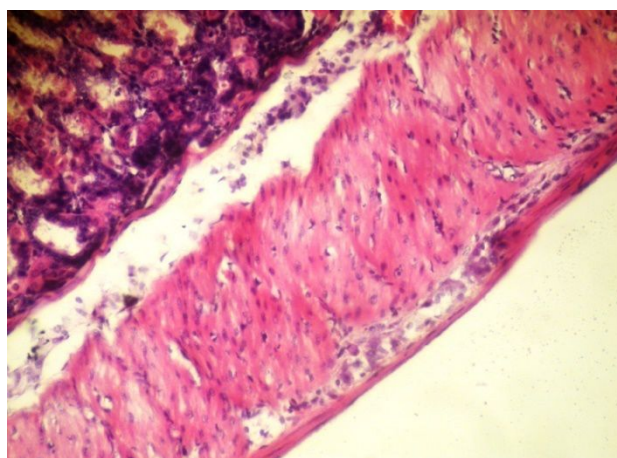
**Tissue sampling:** Stomachs obtained after sacrificing the animal were put in the formalin for histopathological evaluation. These were stored at room temperature.

**Histopathological evaluation of gastric tissues:** Specimens of the gastric walls from each mice were fixed in formalin and processed further through graded ethanol concentration and were embedded in paraffin blocks. Sections of the stomach were made at a thickness of 5 micrometer and stained with hematoxylin and eosin (H&E). Then placed a drop of DPX on the stained slide and cover it by putting

cover slip on it (Bancroft and Gamble, 2002). After staining with hematoxylin and eosin stain (Culling, 1974), the stomach sections were examined under a research microscope.

## RESULTS

In the current study gastroprotective activity of root powder of *G. glabra* was evaluated in male adult albino mice. Results of study revealed that in case of normal control group where animals were not treated with any drug gastric epithelium was intact and there was no sloughing of epithelial cells (Fig. 1). However in case of ulcerogenic group where animals were treated only with aspirin there was a reduced height of villi in the luminal mucosa and in some animals even villi were absent. In the glandular region there was connective tissue proliferation and also infiltration of cells. Similar infiltration of cells was present on muscularis mucosa. In esophageal region tumor cells were present. Hence, epithelial cells were also disrupted due to infiltration of leukocytes (Fig. 2).



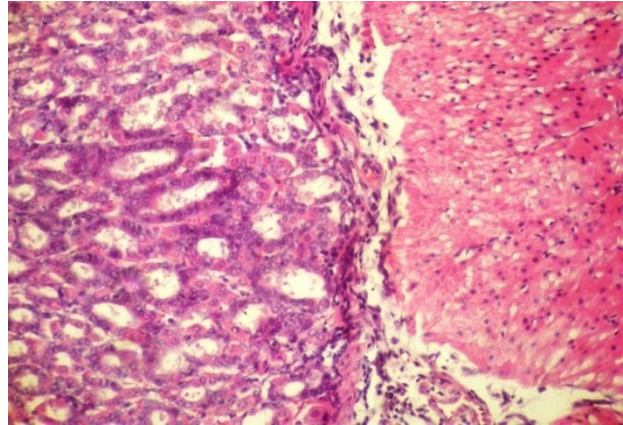
**Figure 1. Photomicrograph of stomach of mice of group 1 showing normal epithelium (H&E 400X).**

Histopathological evaluation in synthetic antiulcer drug

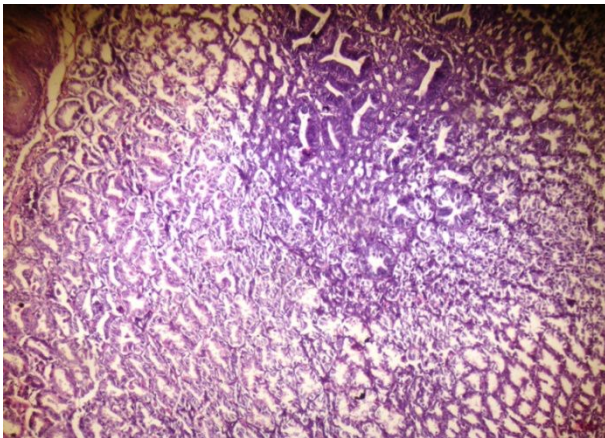
**Table 1. Feeding and Drug Administration schedule in mice during the experimental period of 0-7 days.**

Groups	Treatments
Group1: Control	Routine diet only (0-7 days)
Group2: Untreated control on aspirin 150 mg/kg	Mice were received routine diet + aspirin (0-7 days)
Group 3: Treated control on synthetic antiulcer drug capsule Omega® (omeprazole) 20 mg/kg orally	Mice were received routine diet + aspirin and Omega® (omeprazole) (0-7 days)
Group 4: Treated on <i>G. glabra</i> root powder 250 mg/kg orally	Mice were received routine diet + aspirin and <i>G. glabra</i> root powder (0-7 days)
Group 5: Treated on <i>G. glabra</i> root powder 500 mg/kg orally	Mice were received routine diet + aspirin and <i>G. glabra</i> root powder (0-7 days)
Group 6: Treated on <i>G. glabra</i> root powder 750 mg/kg orally	Mice were received routine diet + aspirin and <i>G. glabra</i> root powder (0-7 days)

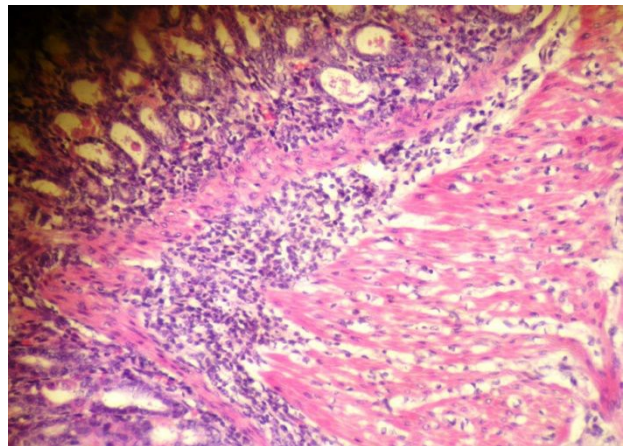
(Omeprazole) treated group showed that there were no pathological changes in epithelial cells of animals and gastric epithelium was intact (Fig. 3). Three different levels of *G. glabra* were used in study to evaluate the gastroprotective activity of *G. glabra* at different levels. In animals treated with lowest dose level (250 mg/kg) of root powder of *G. glabra* mild sloughing of epithelial cells was observed in some animals while epithelial cells of some animals in the same group were normal (Fig. 4). Results also showed that in animals treated with *G. glabra* at a dose level of 500 mg/kg there was no sloughing, hemorrhage and disruption of cells of gastric mucosa (Fig. 5). However from the results it was obvious that in animals treated with highest dose of *G. glabra* (750 mg/kg) there were no pathological changes, edema, necrosis and sloughing, hence the epithelium of gastric mucosa was intact (Fig. 6).



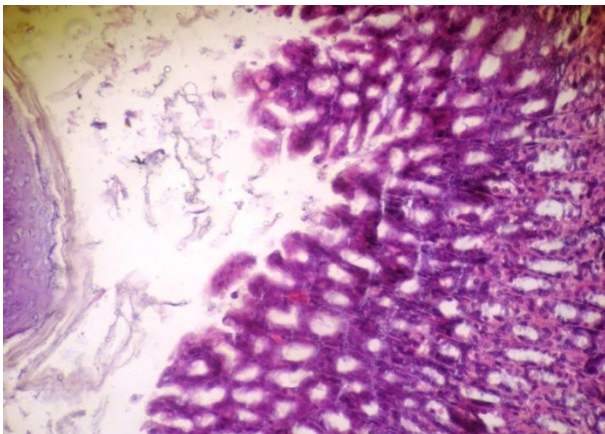
**Figure 4. Photomicrograph of stomach of mice of group 4 showing epithelium sloughing in pyloric region (H&E 200X).**



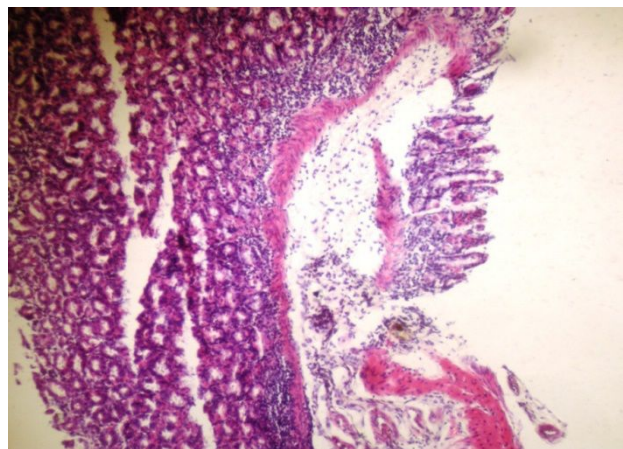
**Figure 2. Photomicrograph of stomach of mice of group 2 showing connective tissue proliferation in the glandular region (H&E 200X).**



**Figure 5. Photomicrograph of stomach of mice of group 5 showing intact epithelium (H&E 200X).**



**Figure 3. Photomicrograph of stomach of mice of group 3 omeprazole showing normal epithelium (H&E 400X).**



**Figure 6. Photomicrograph of stomach of mice of group 6 showing intact epithelium (H&E 200X).**

Results of the study revealed that *G. glabra* in the tested dosages showed no signs and symptoms of toxicity and the results of the study also have pointed out that the test plant showed gastroprotective activity similar as synthetic antiulcer drug omeprazole which is mostly widely used as first line therapy in the treatment of gastric ulcer.

## DISCUSSION

Ulcer is the gastrointestinal disease in which breach is formed in the muscular layer of stomach. A number of people have been affected by this disease every year (Tripathi, 2009). There are several reasons for ulcer production in stomach and duodenum. Recent data has proposed the idea that the non-steroidal anti-inflammatory drugs and *H. pylori* infection are the two most important causative agents for the production of gastric ulcers especially in humans (Rang *et al.*, 2003). NSAIDs related ulcer occurs in 30% of people. It may lead to hospitalization and it may also have the high mortality rate. Aspirin is most frequently used drug of NSAID, despite of its diverse advantageous actions, it also have some harmful side effects. The most commonly occurring adverse effect of aspirin is gastric ulcer. The reason of ulcer related to aspirin is may be the long term use of aspirin or use of aspirin in over dosage. It means that ulcer depends upon the duration or frequency of aspirin used (Soll, 1991; Cryer and Feldman, 1992).

Proton pump inhibitors (omeprazole and lansoprazole) are most commonly used to treat gastric ulcer (Sachs *et al.*, 2006). Omeprazole was used as synthetic antiulcer drug in the above study. It reduced the acid secretions by blocking the hydrogen potassium ATPase pump (Rajeshkumar *et al.*, 2002; Abdulla *et al.*, 2010).

Antiulcer drugs pose severe side effects on withdrawal e.g. relapse, tolerance, nausea and vomiting have been reported in different studies (Choudhary *et al.*, 2001). In the present study antiulcer activity of root powder of *G. glabra* was evaluated against aspirin induced gastric toxicity in male adult albino mice by performing histopathological studies.

Earlier studies on aspirin induced gastric ulcer also showed that aspirin causes the enhanced formation of nitric oxide which leads to gastric epithelial damage. Nitric oxide also acts as defensive factor but in presence of aspirin the amount of nitric oxide (NO) increases which can cause gastric damage (Konturek *et al.*, 2006). Aspirin causes the inflammation of gastric mucosa which leads to leukocyte infiltration by the activation of interleukin pathway which causes excessive entry of leukocytes inside the gastric epithelial linings. This enhanced level of leukocytes inside the gastric mucosa is responsible for inflammation of gastric linings (Jainu *et al.*, 2006; Odashima *et al.*, 2006).

In current study histopathological studies were carried out to evaluate the gastroprotective efficacy of *G. glabra* roots. Results suggested that aspirin severely damaged the gastric

mucosa by disrupting the gastric epithelial linings. It reduced the height of villi inside the luminal mucosa. In the glandular region there was connective tissue proliferation and also infiltration of cells was observed. However similar infiltration of cells was present on muscularis mucosa. In esophageal region tumor cells were also present. Administration of synthetic gastroprotective drug omeprazole significantly reduced the gastric damage and cellular infiltration. However administration of test plant (*G. glabra*) along with aspirin significantly reduced the gastric sloughing, infiltration, edema, hemorrhage and tissue proliferation at three different doses 250, 500 and 750 mg/kg respectively. Hence *G. glabra* at 750 mg/kg showed more effective results as synthetic antiulcer drug omeprazole. The above mentioned results are in accordance with previous studies (Ahmed *et al.*, 2012).

Proposed mechanism for antiulcer activity of *G. glabra* may be the presence of phenolic contents which possesses potent antioxidant and antihistaminergic activity (Zovko *et al.*, 2010; Mohsen *et al.*, 2011). It is suggested that gastro protective activity of plant could be endorsed to its constituents especially to flavonoids which has been proved to be a potent antioxidant. Other constituents of plant drugs that may have role in treatment of ulcer disease include natural phenols, terpenes, tannins, fatty acids etc. (Fiore *et al.*, 2005; Hasanein, 2011).

**Conclusions:** In conclusion, the results have demonstrated the use of plant tested for use in the treatment of gastric ulcer. From the results it is also proved that *G. glabra* has shown no toxicity at the dose levels tested in study. However from the study we can conclude that *G. glabra* can be used as routine therapy in the treatment of gastric ulcer. Results also showed that *G. glabra* has dose dependent gastroprotective activity.

## REFERENCES

- Abdulla, M.A., F.H. AL-Bayat, L.T. Younis and M.I. Hassan. 2010. Anti-ulcer activity of *Centella asiatica* leaf extract against ethanol-induced gastric mucosal injury in rats. *J. Med. Plants Res.* 4:1253-1259.
- Ahmed, S., S.M.S. AlRashdi and N. Asykin. 2012. Mechanisms of gastroprotective effects of ethanolic leaf extract of *Jasminum sambac* against HCl/ethanol-induced gastric mucosal injury in rats. *J. Evid. Based Complementary Altern. Med.* 5:1-24.
- Ahn, S.J., E.J. Cho, H.J. Kim, S.N. Park, Y.K. Lim and J.K. Kook. 2012. The antimicrobial effects of deglycyrrhizinated licorice root extract on *Streptococcus mutans* UA159 in both planktonic and biofilm cultures. *Anaerobe* 18:590-596.
- Asaka, M., M. Kato, T. Sugiyama, K. Satoh, H. Kuwayama, Y. Fukuda, T. Fujioka, T. Takemoto, K. Kimura, T.

- Shimoyama, K. Shimizu and S. Kobayashi. 2003. Follow-up survey of a large-scale multicenter, double-blind study of triple therapy with lansoprazole, amoxicillin, and clarithromycin for eradication of *Helicobacter pylori* in Japanese peptic ulcer patients. *J. Gastroenterol.* 38: 339-347.
- Bancroft, J.D. and M. Gamble. 2002. *Theory and Practice of Histological Techniques*, 5<sup>th</sup> Ed. Edinburgh, Churchill Livingstone.
- Brzozowski, T., S.J. Konturek and S. Kwiecien. 2000. Role of gastric acid secretion in progression of acute gastric erosion induced by ischemia reperfusion into gastric ulcer. *Eur. J. Pharmacol.* 398:147-158.
- Chandrasekaran, C.V., H.B. Deepak, P. Thiyagarajan, S. Kathiresan, G.K. Sangli, M. Deepak and A. Agarwai. 2011. Dual inhibitory effect of *Glycyrrhiza glabra* (GutGard™) on COX and LOX products. *Phytomedicine* 18:278-284.
- Choudhary, A.M., I. Roberts, A. Nagar, S. Tabrez and T. Gupta. 2001. *Helicobacter pylori* related gastric outlet obstruction. *J. Clin. Gastroenterol.* 32:272-273.
- Cryer, B. and M. Feldman. 1992. Effects of nonsteroidal anti-inflammatory drugs on endogenous gastrointestinal prostaglandins and therapeutic strategies for prevention and treatment of non-steroidal, anti-inflammatory drug-induced damage. *Arch. Intern. Med.* 152:1145-1155.
- Culling, C.F. 1994. *Handbook of Histopathological and Histochemical Techniques*, 3<sup>rd</sup> Ed. Butterworth, London.
- Fiore, C., M. Eisenhut, E. Ragazzi, G. Zanchin and D. Armanini. 2005. A history of the therapeutic use of licorice in Europe. *J. Ethnopharmacol.* 99:317-324.
- Gisbert, J.P. and J.M. Pajares. 2005. Systematic review and meta-analysis: Is 1-week proton pump inhibitor-based triple therapy sufficient to heal peptic ulcer. *Aliment. Pharmacol. Ther.* 21:795-804.
- Goel, R.K. and S.K. Bhattacharya. 1991. Gastroduodenal mucosal defense and mucosal protective agents. *Indian J. Exp. Biol.* 29:701-714.
- Hanrahan, C. 2001. *Gale encyclopedia of alternative medicine licorice*. Farmington Hills, MI: Thomson Gale.
- Hasanein, P. 2011. Glabridin as a major active isoflavan from *Glycyrrhiza glabra* (licorice) reverse learning and memory deficits in diabetic rats. *Acta Physiol. Hung.* 98:221-230.
- Herbert, M., C. Jackson, M. Ekpo, E. Okopedi and V. Anah. 2011. Gastroprotective effect of ethanolic leaf extract of *Musa Paradisiaca* in rats. *J. Chem. Pharm. Res.* 3:322-327.
- Holtmann, G. and C.W. Howden. 2004. Review article: Management of peptic ulcer bleeding-the role of proton pump inhibitors and *Helicobacter pylori* eradication. *Aliment. Pharmacol. Ther.* 1: 66-70.
- Hoogerwerf, W.A. and P.J. Pasricha. 2001. Agents used to control of gastric acidity and treatment of peptic ulcers and gastroesophageal reflux disease; pp.1005-1020. In: Goodman and Gilman's (10<sup>th</sup> Ed.), *The Pharmacological Basis of Therapeutics*. Pergamon Press, New York 10523, USA.
- Huang, W., X. Chen, Q. Li, P. Li, G.N. Zhao, M.M. Xu and P. Xie. 2012. Inhibition of intercellular adhesion in herpes simplex virus infection by glycyrrhizin. *Cell Biochem. Biophys.* 62:137-140.
- Jainu, M., K.V. Mohan and C.S.S. Devi. 2006. Gastroprotective effect of *Cissus quadrangularis* extract in rats with experimentally induced ulcer. *Indian J. Med. Res.* 123:799-806.
- Konturek, P.C., J. Kania, E.G. Hahn and J.W. Konturek. 2006. Ascorbic acid attenuates aspirin-induced gastric damage: role of inducible nitric oxide synthase. *J. Physiol. Pharmacol.* 57:125-136.
- Kusters, J.G., A.H.M. Vliet and E.J. Kuipers. 2006. Pathogenesis of *Helicobacter pylori* infection. *Clin. Microbiol. Rev.* 19:449-490.
- Li, S., J.H. Zhu, L.P. Cao, Q. Sun, H.D. Liu, W.D. Li, J.S. Li and C.H. Hang. 2014. Growth inhibitory in vitro effects of glycyrrhizic acid in U251 glioblastoma cell line. *Neurol. Sci.* 35:1115-20.
- Long, D.R., J. Mead, J.M. Hendricks, M.E. Hardy and J.M. Voyich. 2013. 18 $\beta$ -Glycyrrhetic acid inhibits methicillin-resistant staphylococcus aureus survival and attenuates virulence gene expression. *Antimicrob. Agents Ch.* 57:241-247.
- Malfertheiner, P., F. Megraud, C.O. Morain, F. Bazzoli, E. El-Omar, D. Graham, R. Hunt, T. Rokkas, N. Vakil and E.J. Kuipers. 2007. Current concepts in the management of *Helicobacter pylori* infection: The Maastricht III Consensus Report. *Gut.* 56:772-781.
- Mohsen, M., A. Ghannadi, P. Mahzouni and E.J. Shirazi. 2011. Comparative study of *Berberis vulgaris* fruit extract and berberine chloride effects on acetic acid induced colitis in rats. *Iran. J. Pharm. Res.* 10:97-104.
- Odashima, M., M. Otaka, M. Jin, K. Komatsu, I. Wada and Y. Horikawa. 2006. Attenuation of gastric mucosal inflammation induced by aspirin through activation of adenosine receptor in rats. *World J. Gastroenterol.* 12:568-573.
- Padussis, J.C. and T.N. Pappas. 2010. Management of bleeding peptic ulcer disease. In: A. D. Pryor, T.N. Pappas and M.S. Branch (eds.), *Gastrointestinal Bleeding: Practical approach to diagnosis and management*, pp.39-64.
- Rajeshkumar, N.V., K.L. Joy, G. Kuttan, R.S. Ramsewak, M.G. Nair and R. Kuttan. 2002. Anticarcinogenic activity of *Phyllanthusamarus* extract. *J. Ethnopharmacol.* 81:17-22.

- Rang, H.P., M.M. Dale, M. Ritter and P.K. Moore. 2003. Pharmacology, 5<sup>th</sup> Ed. Churchill, Livingstones, Edinburgh.
- Sachs, G., J.M. Shin and C.W. Howden. 2006. The clinical pharmacology of proton pump inhibitors. *Aliment. Pharmacol. Ther.* 23:2–8.
- Seki, H., S. Sawai, K. Ohyama, M. Mizutanig, T. Ohnishig, H. Sudo, E.O. Fukushima, T. Akashi, T. Aoki, K. Saito and T. Muranaka. 2011. Triterpene functional genomics in licorice for identification of CYP72A154 involved in the biosynthesis of glycyrrhizin. *Plant Cell Online* 23:4112-4123.
- Shin, Y.W., E.A. Bae, B. Lee, S.H. Lee, J.A. Kim, Y.S. Kim and D.H. Kim. 2007. *In vitro* and *in vivo* antiallergic effects of *Glycyrrhiza glabra* and its components. *Planta Med.* 73:257-261.
- Soll, A.H. 1991. Moderator: Nonsteroidal anti-inflammatory drugs and peptic ulcer disease. *Ann. Intern. Med.* 114:307–319.
- Tripathy, M., B.K. Singh and P. Kakkar. 2009. Glycyrrhizic acid modulates t-BHP induced apoptosis in primary rat hepatocytes. *Food Chem. Toxicol.* 47:339-347.
- Wang, Z., Y. Cao, S. Paudel, G. Yoon and S.H. Cheon. 2013. Concise synthesis of licochalcone C and its regioisomer, licochalcone H. *Arch. Pharm. Res.* 36:1432-1436.
- Zovko, M., D. Kremer, K. Karlovic and I. Kosalec. 2010. Evaluation of antioxidant activities and phenolic content of *Berberis vulgaris* and *Berberis croatica* horvat. *Food Chem. Toxicol.* 48:2176-2180.